



# COVID-19 and the kidney: what we think we know so far and what we don't

Samira S. Farouk<sup>1</sup> · Enrico Fiaccadori<sup>2</sup> · Paolo Cravedi<sup>1</sup> · Kirk N. Campbell<sup>1</sup>

Received: 25 May 2020 / Accepted: 20 June 2020  
© Italian Society of Nephrology 2020

## Abstract

The novel coronavirus disease infection (COVID-19) outbreak that was declared a global pandemic in March 2020 had led to an internationally variable but concerning incidence of COVID-associated acute kidney injury (AKI), with prevalence reported as high as 46% in large cohorts of hospitalized patients. Variability in AKI may be explained by differences in traditional risk factors for AKI, heterogeneity among patient cohorts, and differences in racial and ethnic groups. Further, AKI requiring kidney replacement therapies (KRT) has been associated with increased mortality. Proposed mechanisms of kidney injury include direct viral-induced tubular or glomerular injury, sepsis-associated AKI, and thrombotic disease. Kidney pathology include acute tubular injury, glomerular fibrin thrombi, pigmented tubular casts, and collapsing focal segmental glomerulosclerosis. “Viral-like” particles have been observed in renal samples at electron microscopy and viral RNA has been identified in both glomerular and tubular compartments of kidney specimens, but the link between viral presence and injury remain unclear. Though the link between AKI and poor outcomes is clear, prevalence and outcomes of COVID-19 in patients with chronic kidney disease and end stage kidney disease has not yet been reported. In patients on immunosuppression like those with kidney transplants or glomerular disease, COVID-19 has presented a management dilemma. Herein, we review the existing literature on kidney disease in COVID-19 and discuss what remains to be learned.

**Keywords** SARS-CoV2 · Kidney transplant · Acute kidney injury · COVID-19

## Introduction

The novel coronavirus disease infection (COVID-19) outbreak, caused by severe acute respiratory syndrome coronavirus 2 (SARS-CoV2), began in Wuhan, Hubei Province, China in December 2019 and was declared a global pandemic on March 11, 2020 by the World Health Organization (WHO). Though the initial focus of research has been on pulmonary pathophysiology, observed acute kidney injury (AKI) prevalence and associated mortality [1] has been high in some reports—particularly AKI requiring kidney replacement therapies (KRT). Herein, we discuss what has been

reported about kidney disease in COVID-19, and what remains to be discovered and lies ahead.

## The true incidence of acute kidney injury?

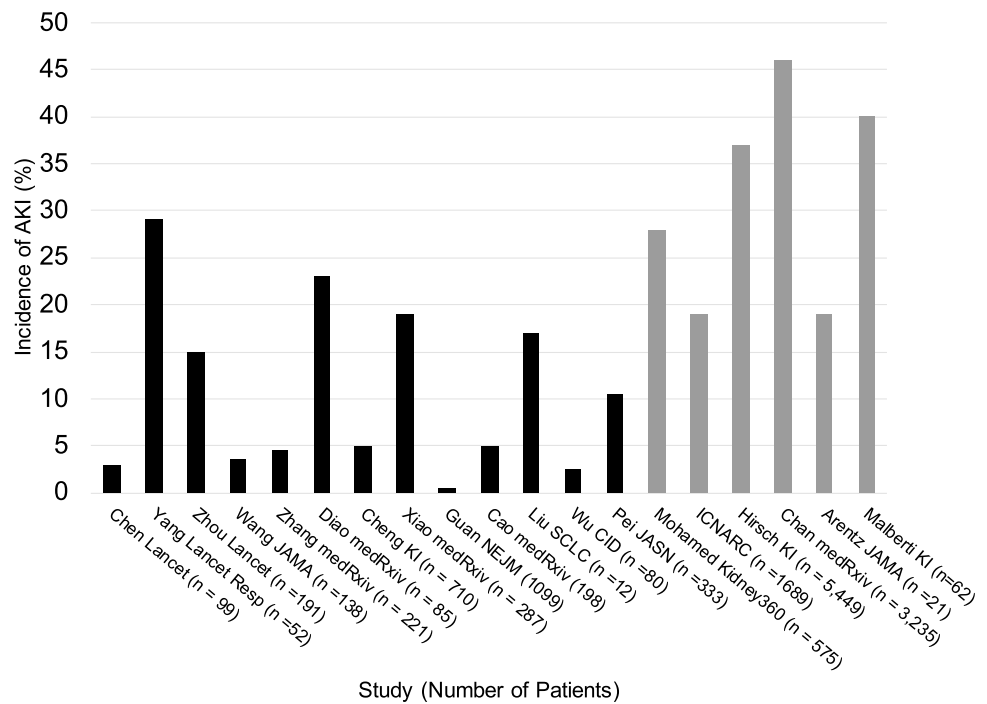
Though findings from several patient populations have been reported, the true incidence of AKI in COVID-19 remains unknown. Existing data, while heterogeneous with respect to population size, location, severity of illness, and definitions of AKI, show a wide range of rates of AKI occurrence in patients with COVID-19 from 1 to 46% (Fig. 1 [1–18]). At our institution, the incidence of AKI in 3325 patients with COVID-19 was 46%—with 20% requiring KRT [19]. In the largest cohort of 5449 hospitalized patients with COVID-19 studied so far, the proportion of patients with AKI any stage was 1993 (31.1%) [14]. Few European data are currently available on this topic. In a cohort of 62 patients not on maintenance dialysis in Lombardy, Italy, 40% developed AKI and 10% required KRT [18]. In this cohort, a mortality rate of 88% was

✉ Kirk N. Campbell  
kirk.campbell@mssm.edu

<sup>1</sup> Division of Nephrology, Department of Medicine, Icahn School of Medicine at Mount Sinai, Box 1243, One Gustave L. Levy Place, 10029 New York, NY, USA

<sup>2</sup> Acute and Chronic Renal Failure Unit, Department of Clinical and Experimental Medicine, University of Parma, Parma, Italy

**Fig. 1** Incidence of acute kidney injury (AKI) reported in China (black bars), Ireland, United Kingdom, Wales, and United States. Three studies included only patients requiring intensive care [1, 12, 13] while others included hospitalized patients



reported in patients with advanced chronic kidney disease (CKD). In a large tertiary care hospital (Parma University Hospital, Parma, Italy) with 800 medicine beds and 60 COVID-19-dedicated ICU beds, 120 COVID-19 patients were admitted to the ICU between February 23rd to May 5th. AKI (as defined by the 2019 Kidney Diseases: Improving Global Outcomes Consensus Conference [20]) was observed in 26/120 (21.7%) before or at ICU admission, and in 29/126 (24.2%) during ICU stay; four patients (4/120, 3.3%) underwent KRT, performed as sustained low-efficiency dialysis (SLED) with regional citrate anticoagulation (personal communication).

Not surprisingly, there are noticeable differences in AKI rates between not only different countries, but also among those studies that included all hospitalized patients compared to those which analyzed only patients required intensive care. Similarly, the percentage of those requiring KRT widely varied from 0 to 23.2% [21]. Potential explanations for these differences include the prevalence of co-morbid conditions and heterogeneity along racial and ethnic lines, local institutional policies about KRT timing, the use of extracorporeal KRT beyond classical “nephrological” indications. One study reported that of the five New York City boroughs, the Bronx had not only higher rates of mortality, but also the highest proportion of racial and ethnic minoritized groups, most persons living in poverty, and lowest levels of educational attainment [22].

## A proposed pathogenesis of kidney injury

In a relatively short period of time, several case reports and two series of post-mortem tissue sample analysis from China have begun to shed some light on potential mechanisms of kidney injury associated with COVID-19, even though many open issues remain (Table 1 [23–26]).

It is still not clearly ascertained whether SARS-CoV-2 directly damages the kidney injury or if kidney injury results from complications arising in the course of the viral infection outside the kidney. Reports of urinary abnormalities in COVID-19 patients, positive staining of tubules with viral antigens and complement components in one autopsic series, visualization of viral particles in tubular epithelial cells and podocytes on ultrastructural examination in other kidney biopsies and isolation of SARS-CoV-2 in urine, raised the possibility of a “SARS-CoV-2 nephropathy” (Table 1). In a kidney histological analysis of the largest autopsy series so far on 26 patients with COVID-19 from China [27], acute tubular injury ranging from mild to severe was almost always observed. Three biopsy specimens revealed segmental glomerular fibrin thrombi, 3 had pigmented tubular casts, and 7 were thought to have viral-like particles identified under electron microscopy (EM). What was perhaps most interesting of this study was that only 9/26 (34.6%) showed clinical

**Table 1** Summary of evidence in favor of and against direct SARS-CoV-2-mediated pathogenesis of acute kidney injury (AKI)

Suggests direct viral involvement	Against direct viral involvement	Comments
<p>Urinalysis abnormalities</p> <p>Urinalysis abnormalities (proteinuria, hematuria) commonly occur in the patients with COVID-19 [17]</p>	<p>Transient proteinuria and hematuria are common in critically ill patients</p>	<p>Pathophysiology of proteinuria during septic shock remains still largely unclear. Release of several proinflammatory cytokines into the systemic circulation may lead to: a. Generalized loss of endothelial cells barrier integrity and subsequent capillary leak; b. Altered tubular handling of filtered albumin, promoting albuminuria; c. Podocyte cytoskeleton disruption and apoptosis</p>
<p>Glomerular and tubulointerstitial injury</p> <p>Evidence of diffuse proximal tubule injury with loss of brush border, non-isometric vacuolar degeneration, and necrosis was reported in patients with COVID-19. In addition, erythrocyte aggregates obstructing the lumen of capillaries without platelet or fibrinoid material were present [22]</p> <p>Postmortem biopsies from patients with AKI showed severe ATN and lymphocyte/macrophage infiltration, along with positive viral antigen NP staining of tubules and complement components [5]</p>	<p>Immunohistochemical analysis of postmortem kidney biopsies in AKI associated with septic shows neutrophils and macrophages in the glomeruli, and neutrophils in the tubulointerstitium. Cell proliferation and fibrin deposition are pronounced in the glomeruli and tubulointerstitium of sepsis-associated AKI [23, 24]</p> <p>Absence of viral detection by in situ RNA analysis in the kidney biopsies from two COVID-19 positive cases with collapsing glomerulopathy [33, 34]</p> <p>Absence of virus in serum, urine and kidney tissue by real-time RT-PCR, despite repeatedly positive nasopharyngeal swabs in a critically ill patient with ARDS and AKI [31]</p>	<p>Considering the many complications that can induce acute tubulointerstitial injury in ICU patients with ARDS and AKI, the causal relationship between viral infection and tubular damage is questionable</p> <p>Acute tubular injury by light microscopy in autopsy series might represent autolysis, almost invariably observed in autopsy kidneys</p>
<p>Viral kidney tropism</p> <p>Clusters of coronavirus-like particles with distinctive spikes in the tubular epithelium of the kidney were observed in EM specimens from an autopsy series [5, 22] and a native kidney biopsy [27]</p>	<p>Putative coronavirus particles were present, though all other tests for coronavirus in kidney were negative [27]</p> <p>Multivesicular bodies (MVB) mimicking SARS-CoV-2 can be found in podocytes from COVID-19 negative patients, irrespective of the underlying kidney disease [22]</p> <p>In a COVID-19 patient with collapsing glomerulopathy, “viral particles” were described as tubuloreticular inclusions in the endothelial cells and podocytes (with the appearance of MVB), but no viral RNA signal was detected in biopsy tissue [27]</p>	<p>Many cellular components and structures can masquerade as viruses. In fact, transmission EM of tissue sections are not specific or sensitive for viral particle detection, as many intracellular structures observed in podocytes and endothelial cells resemble viruses (“viral-like particles”). For example, endothelial tubuloreticular inclusions also called myxovirus-like particles [22]</p> <p>Purported virus particles in the cytoplasm of kidney tubular epithelium and podocytes could represent clathrin-coated vesicles, which are normal cell organelles involved in intracellular transport [23]</p>
<p>Viral nephrotoxic effects</p> <p>SARS-CoV-2 viral load has been quantified in autopsy kidneys, together with single cell RNA sequencing of viral receptors in kidney specimens and in situ hybridization. This analysis has revealed viral RNA in microdissected portions of the same specimens, thus suggesting both viral entry and replication into kidney cells [29]</p>	<p>Viral entry and replication do not necessarily translate into cytopathic damage, as best exemplified by other viral infections such as HIV [24]</p> <p>SARS-CoV, whose genome is largely similar to that of SARS-CoV-2, was shown to be capable of entering kidney cells and replicating—but did not cause apparent harm [25]</p>	<p>There has not yet been reproducible proof of viral tropism with active infection, which would require the concurrent demonstration of kidney cell infection (i.e. viral entry) together with viral replication/cytopathy</p>

ICU intensive care unit, ARDS acute respiratory distress syndrome, ATN acute tubular necrosis, RNA ribonucleic acid, EM electron microscopy, COVID-19 novel corona virus disease infection

signs of AKI and 5/26 (19.2%) required KRT. Acute tubular necrosis may be related to a similar presentation as seen with sepsis-induced AKI, mediated by the inflammatory milieu [28, 29]. Sixteen patients out of 26 (61.5%) of patients were hypotensive or required vasopressor support, thus making poor perfusion another likely mechanism of tubular injury. Could SARS-CoV2 itself be playing a role in tubular injury? Viral entry via angiotensin converting enzyme 2 (ACE2), expressed on proximal tubular cells, seems to support such a hypothesis [30, 31]. Additional support of this theory comes from the observation of spherical viral particles characteristic of viral inclusions on EM [27, 32, 33] as well as viral ribonucleic acid (RNA) detection [6] in the kidney. Of note, the presence of presumed viral particles and RNA have not been consistently reported throughout the literature (Table 1), and many cell structures could mimic the virus itself (Table 1). Whether or not the presence of virus is an incidental finding or indeed contributing to pathology has not been determined. One recent study detected SARS-CoV-2 in the kidneys of autopsy specimens using in situ hybridization and indirect immunofluorescence [34]. They noted preferential targeting of glomerular cells in the kidney, with viral detection also in liver, heart, brain, blood and most highly in the respiratory tract. It is likely, as suggested by the authors, that multiorgan tropism influences the course of COVID-19.

The presence of fibrin thrombi typically points towards a diagnosis of thrombotic microangiopathy (TMA), though the hypercoagulable state in patients with COVID-19 raises the likelihood of thrombi both in pulmonary blood vessels [35] and within microvasculature of the kidney. It is also possible that thrombotic occlusion of large kidney blood vessels (e.g. renal artery, renal vein) may contribute to kidney injury. A kidney biopsy from a critically ill patient with COVID-19 showed a classical pattern of acute tubular injury (ATI) with marked regenerative changes and focal acute tubular necrosis (ATN) [36].

Evidence of glomerular injury in patients with COVID-19 also exist, as documented by the presence of proteinuria or hematuria in up to 60% of the cases in some series [37]. Though not reported in the autopsy series, several reports of collapsing focal segmental glomerulosclerosis (FSGS) have been published [32, 38, 39]. Two out of 3 reported the presence of 2 high-risk *APOL1* alleles in these patients. Similar to other viral-associated collapsing FSGS (e.g. human immunodeficiency virus (HIV), parvovirus 19) tubuloreticular inclusions suggesting systemic interferon activity [40] were reported.

Like the majority of kidney diseases, the mechanisms are most likely to be multifactorial and data thus far point to contributions from direct viral infection, inflammatory syndrome-mediated injury, hemodynamic instability, and perhaps the hypercoagulable state.

## COVID-19 and special populations

### Chronic kidney disease (CKD) and end-stage kidney disease (ESKD)

It is not yet known whether CKD or ESKD are a significant risk factors for COVID-19 infection and associated hospitalizations. While the development of AKI is associated with increased in-hospital mortality, hospitalized patients with a prior history of ESKD do not appear to require the same rate of intensive unit level care anecdotally. Though immune dysfunction (both immunosuppression and overactivation) have been described in this population [41], it is possible that ESKD patients do not mount the same cytokine storm response implicated in multiorgan dysfunction noted in critically ill patients. Mortality data on this patient populations remains limited, though a 30% mortality rate was reported in a cohort of 20 hemodialysis patients with COVID-19 [18]. In a large cohort of patients in New York City, patients with CKD and either atrial fibrillation, heart failure, or ischemic heart disease had a higher mortality rate. [42]. In an Italian cohort, 94 patients on hemodialysis with COVID-19 who were managed as either inpatient or outpatient had mortality rates of 42% and 8%, respectively [43]. At our outpatient hemodialysis center, we found an incidence and mortality rate of 17.5% and 3.6%, respectively.

### Transplant

Kidney transplant recipients appear to be at higher risk for hospitalization and death from COVID-19. Similar to incidence rates of AKI, reported mortality rates in this population have varied and as high as 28% [22, 44]. There is an absence of consensus about how to adjust immunosuppression in Covid-19 kidney transplant recipients. While immunosuppression may prevent an effective anti-SARS-CoV-2 T cell response, it may also allow controlling inflammatory response that is, at least in part, responsible for COVID-19 related mortality. Calcineurin inhibitors, the backbone of the majority of immunosuppression regimens, have shown in vitro activity against coronaviruses—though clinical data are lacking [45]. At our center, our approach has been to maintain both corticosteroids and anti-metabolite immunosuppressive therapy while lowering calcineurin trough targets. While most centers reduce immunosuppression, approaches vary significantly from institution to institution [46].

## Glomerular disease

The impact of COVID-19 on glomerular disease patients remains unclear. An individualized risk–benefit analysis to reduce, defer, or maintain immunosuppression seems appropriate. Some centers, including our own, have noted a marked reduction in rapidly progressive glomerulonephritis cases and urgent kidney biopsies during widespread home quarantining—supporting an environmental component in exacerbating glomerular disease [47].

## A look to the future

Several months into the COVID-19 pandemic, there is much that we do not understand. The relationship between acute kidney injury and multiorgan failure is unclear. Details on the contribution of hypercoagulability, complement activation and endothelial injury to organ dysfunction are lacking. Presentation of a catabolic state in patients with COVID-19 [48] raises the possibility of acquired metabolic or mitochondrial disorders, in addition to the impact of cytokines and the inflammatory state on these pathways. Though this catabolic state seems to mimic rhabdomyolysis, creatine phosphokinase (CPK) levels have not been found to be dramatically elevated. While ACE2 plays an important role in viral cellular entry, proposed angiotensin dysregulation, innate and adaptive immune pathway activation, and hypercoagulation have emerged as proposed mechanisms of kidney and other organ injury [49]. Most concerning is the high level of residual kidney dysfunction in patients who have recovered from COVID-19. We are yet to fully appreciate their long-term risk for progression to end-stage kidney disease or whether the virus like HIV, could use kidney epithelial cells as a reservoir. A better understanding of kidney disease pathophysiology may aid in the development of effective therapies. As we move forward, it is plausible that computational biology will be important in understanding COVID-19 pathophysiology in identifying both therapies and innovative strategies to design a vaccine [50].

## Compliance with ethical standards

**Conflict of interest** This manuscript has not been published previously, in whole or part. The authors have no conflicts of interest to disclose.

**Ethical approval** This article does not contain any studies with human participants or animals performed by any of the authors.

**Informed consent** For this type of study formal consent is not required.

## References

- Cheng Y, Luo R, Wang K et al (2020) Kidney disease is associated with in-hospital death of patients with COVID-19. *Kidney Int* 97:829–838. <https://doi.org/10.1016/j.kint.2020.03.005>
- Yang X, Yu Y, Xu J et al (2020) Clinical course and outcomes of critically ill patients with SARS-CoV-2 pneumonia in Wuhan, China: a single-centered, retrospective, observational study. *Lancet Respir Med*. [https://doi.org/10.1016/S2213-2600\(20\)30079-5](https://doi.org/10.1016/S2213-2600(20)30079-5)
- Zhou F, Yu T, Du R et al (2020) Clinical course and risk factors for mortality of adult inpatients with COVID-19 in Wuhan, China: a retrospective cohort study. *Lancet* 395:1054–1062. [https://doi.org/10.1016/S0140-6736\(20\)30566-3](https://doi.org/10.1016/S0140-6736(20)30566-3)
- Wang L, Li X, Chen H et al (2020) Coronavirus disease 19 infection does not result in acute kidney injury: an analysis of 116 hospitalized patients from Wuhan, China. *Am J Nephrol*. <https://doi.org/10.1159/000507471>
- Wang D, Hu B, Hu C et al (2020) Clinical characteristics of 138 hospitalized patients with 2019 novel coronavirus-infected pneumonia in Wuhan, China. *JAMA* 323:1061–1069. <https://doi.org/10.1001/jama.2020.1585>
- Diao B, Wang C, Wang R et al (2020) human kidney is a target for novel severe acute respiratory syndrome coronavirus 2 (SARS-CoV-2) infection. *medRxiv*. <https://doi.org/10.1101/2020.03.04.20031120>
- Xiao G, Hu H, Wu F et al (2020) Acute kidney injury in patients hospitalized with COVID-19 in Wuhan, China: a single-center retrospective observational study. *medRxiv*. <https://doi.org/10.1101/2020.04.06.20055194>
- Guan W, Ni Z, Hu Y et al (2020) Clinical characteristics of coronavirus disease 2019 in China. *N Engl J Med* 382:1708–1720. <https://doi.org/10.1056/NEJMoa2002032>
- Cao M, Zhang D, Wang Y et al (2020) Clinical features of patients infected with the 2019 novel coronavirus (COVID-19) in Shanghai, China. *medRxiv*. <https://doi.org/10.1101/2020.03.04.20030395>
- Liu Y, Yang Y, Zhang C et al (2020) Clinical and biochemical indexes from 2019-nCoV infected patients linked to viral loads and lung injury. *Sci China Life Sci* 63:364–374. <https://doi.org/10.1007/s11427-020-1643-8>
- Wu J, Liu J, Zhao X et al (2020) Clinical characteristics of imported cases of COVID-19 in Jiangsu Province: a multicenter descriptive study. *Clin Infect Dis Off Publ Infect Dis Soc Am*. <https://doi.org/10.1093/cid/ciaa199>
- Arentz M, Yim E, Klaff L et al (2020) Characteristics and outcomes of 21 critically ill patients with COVID-19 in Washington State. *JAMA* 323:1612–1614. <https://doi.org/10.1001/jama.2020.4326>
- ICNARC—Intensive Care National Audit & Research Centre. <https://www.icnarc.org/>. Accessed 20 May 2020
- Hirsch JS, Ng JH, Ross DW et al (2020) Acute kidney injury in patients hospitalized with COVID-19. *Kidney Int*. <https://doi.org/10.1016/j.kint.2020.05.006>
- Mohamed MM, Lukitsch I, Torres-Ortiz AE et al (2020) Acute kidney injury associated with coronavirus disease 2019 in urban New Orleans. *Kidney*. <https://doi.org/10.34067/KID.0002652020>
- Pei G, Zhang Z, Peng J et al (2020) Renal involvement and early prognosis in patients with COVID-19 pneumonia. *J Am Soc Nephrol*. <https://doi.org/10.1681/ASN.2020030276>
- Chen N, Zhou M, Dong X et al (2020) Epidemiological and clinical characteristics of 99 cases of 2019 novel coronavirus pneumonia in Wuhan, China: a descriptive study. *Lancet* 395:507–513. [https://doi.org/10.1016/S0140-6736\(20\)30211-7](https://doi.org/10.1016/S0140-6736(20)30211-7)
- Malberti F, Pecchini P, Marchi G, Foramitti M (2020) When a nephrology ward becomes a COVID-19 ward: the Cremona

- experience. *J Nephrol*. <https://doi.org/10.1007/s40620-020-00743-y>
19. Chan L, Chaudhary K, Saha A et al (2020) Acute kidney injury in hospitalized patients with COVID-19. medRxiv. <https://doi.org/10.1101/2020.05.04.20090944>
  20. Levey AS, Eckardt K-U, Dorman NM et al (2020) Nomenclature for kidney function and disease: report of a kidney disease: improving global outcomes (KDIGO) consensus conference. *Kidney Int* 97:1117–1129. <https://doi.org/10.1016/j.kint.2020.02.010>
  21. Acute Kidney Injury. In: *NephJC*. <http://www.nephjc.com/news/covidaki>. Accessed 4 May 2020
  22. Akalin E, Azzi Y, Bartash R et al (2020) Covid-19 and kidney transplantation. *N Engl J Med*. <https://doi.org/10.1056/NEJMc2011117>
  23. Calomeni E, Satoskar A, Ayoub I et al (2020) Multivesicular bodies mimicking SARS-CoV-2 in patients without COVID-19. *Kidney Int*. <https://doi.org/10.1016/j.kint.2020.05.003>
  24. Miller SE, Brealey JK (2020) Visualization of putative coronavirus in kidney. *Kidney Int*. <https://doi.org/10.1016/j.kint.2020.05.004>
  25. Aiamkitsumrit B, Sullivan NT, Nonnemacher MR et al (2015) Human immunodeficiency virus type 1 cellular entry and exit in the T lymphocytic and monocytic compartments: mechanisms and target opportunities during viral disease. *Adv Virus Res* 93:257–311. <https://doi.org/10.1016/bs.aivir.2015.04.001>
  26. Pacciarini F, Ghezzi S, Canducci F et al (2008) Persistent replication of severe acute respiratory syndrome coronavirus in human tubular kidney cells selects for adaptive mutations in the membrane protein. *J Virol* 82:5137–5144. <https://doi.org/10.1128/JVI.00096-08>
  27. Su H, Yang M, Wan C et al (2020) Renal histopathological analysis of 26 postmortem findings of patients with COVID-19 in China. *Kidney Int*. <https://doi.org/10.1016/j.kint.2020.04.003>
  28. Lerolle N, Nochy D, Guérot E et al (2010) Histopathology of septic shock induced acute kidney injury: apoptosis and leukocytic infiltration. *Intensive Care Med* 36:471–478. <https://doi.org/10.1007/s00134-009-1723-x>
  29. Aslan A, van den Heuvel MC, Stegeman CA et al (2018) Kidney histopathology in lethal human sepsis. *Crit Care* 22:359. <https://doi.org/10.1186/s13054-018-2287-3>
  30. Bourgonje AR, Abdulle AE, Timens W et al (2020) Angiotensin-converting enzyme-2 (ACE2), SARS-CoV-2 and pathophysiology of coronavirus disease 2019 (COVID-19). *J Pathol*. <https://doi.org/10.1002/path.5471>
  31. Brojakowska A, Narula J, Shimony R, Bander J (2020) Clinical implications of SARS-COV2 interaction with renin angiotensin system. *J Am Coll Cardiol*. <https://doi.org/10.1016/j.jacc.2020.04.028>
  32. Kissling S, Rotman S, Gerber C et al (2020) Collapsing glomerulopathy in a COVID-19 patient. *Kidney Int*. <https://doi.org/10.1016/j.kint.2020.04.006>
  33. Varga Z, Flammer AJ, Steiger P et al (2020) Endothelial cell infection and endotheliitis in COVID-19. *Lancet* 395:1417–1418. [https://doi.org/10.1016/S0140-6736\(20\)30937-5](https://doi.org/10.1016/S0140-6736(20)30937-5)
  34. Puelles VG, Lütgehetmann M, Lindenmeyer MT et al (2020) Multiorgan and renal tropism of SARS-CoV-2. *N Engl J Med*. <https://doi.org/10.1056/NEJMc2011400>
  35. Connors JM, Levy JH (2020) Thromboinflammation and the hypercoagulability of COVID-19. *J Thromb Haemost JTH*. <https://doi.org/10.1111/jth.14849>
  36. Rossi GM, Delsante M, Pilato FP et al (2020) Kidney biopsy findings in a critically ill COVID-19 patient with dialysis-dependent acute kidney injury: a case against “SARS-CoV-2 nephropathy”. *Kidney Int Rep*. <https://doi.org/10.1016/j.ekir.2020.05.005>
  37. Li Z, Wu M, Volunteers A-2019-nCoV et al (2020) Caution on kidney dysfunctions of COVID-19 patients. medRxiv. <https://doi.org/10.1101/2020.02.08.20021212>
  38. Larsen CP, Bourne TD, Wilson JD et al (2020) Collapsing glomerulopathy in a patient with coronavirus disease 2019 (COVID-19). *Kidney Int Rep*. <https://doi.org/10.1016/j.ekir.2020.04.002>
  39. Peleg Y, Kudose S, D’Agati V et al (2020) Acute kidney injury due to collapsing glomerulopathy following COVID-19 infection. *Kidney Int Rep*. <https://doi.org/10.1016/j.ekir.2020.04.017>
  40. Bromfield M, McQuillan R, John R, Avila-Casado C (2014) The significance of tubuloreticular inclusions as a marker of systemic stimulation by interferons in a case of focal and segmental glomerulosclerosis associated with cytomegalovirus (CMV) infection. *Clin Kidney J* 7:174–178. <https://doi.org/10.1093/ckj/sft156>
  41. Kato S, Chmielewski M, Honda H et al (2008) Aspects of immune dysfunction in end-stage renal disease. *Clin J Am Soc Nephrol CJASN* 3:1526–1533. <https://doi.org/10.2215/CJN.00950208>
  42. Yamada T, Mikami T, Chopra N et al (2020) Patients with chronic kidney disease have a poorer prognosis of coronavirus disease 2019 (COVID-19): an experience in New York City. *Int Urol Nephrol*. <https://doi.org/10.1007/s11255-020-02494-y>
  43. Alberici F, Delbarba E, Manenti C et al (2020) A report from the Brescia Renal COVID Task Force on the clinical characteristics and short-term outcome of hemodialysis patients with SARS-CoV-2 infection. *Kidney Int*. <https://doi.org/10.1016/j.kint.2020.04.030>
  44. Alberici F, Delbarba E, Manenti C et al (2020) A single center observational study of the clinical characteristics and short-term outcome of 20 kidney transplant patients admitted for SARS-CoV2 pneumonia. *Kidney Int* 97:1083–1088. <https://doi.org/10.1016/j.kint.2020.04.002>
  45. Willicombe M, Thomas D, McAdoo S (2020) COVID-19 and calcineurin inhibitors: should they get left out in the storm? *J Am Soc Nephrol* 31:1145–1146. <https://doi.org/10.1681/ASN.2020030348>
  46. Fishman JA, Grossi PA (2020) Novel coronavirus-19 (COVID-19) in the immunocompromised transplant recipient: #Flatteningthecurve. *Am J Transplant* 20:1765–1767. <https://doi.org/10.1111/ajt.15890>
  47. Bomback AS, Canetta PA, Ahn W et al (2020) How COVID-19 has changed the management of glomerular diseases. *Clin J Am Soc Nephrol*. <https://doi.org/10.2215/CJN.04530420>
  48. Billah M, Santeusanio A, Delaney V et al (2020) A catabolic state in a kidney transplant recipient with COVID-19. *Transpl Int Off J Eur Soc Organ Transpl*. <https://doi.org/10.1111/tri.13635>
  49. Battle D, Soler MJ, Sparks MA et al (2020) Acute kidney injury in COVID-19: emerging evidence of a distinct pathophysiology. *J Am Soc Nephrol*. <https://doi.org/10.1681/ASN.2020040419>
  50. Oberg AL, Kennedy RB, Li P et al (2011) Systems biology approaches to new vaccine development. *Curr Opin Immunol* 23:436–443. <https://doi.org/10.1016/j.coi.2011.04.005>

**Publisher’s Note** Springer Nature remains neutral with regard to jurisdictional claims in published maps and institutional affiliations.